

Bilateral Evisceration: A Case Report

ABSTRACT: *A case of bilateral evisceration is described. Each individual copes in a unique way to the loss of an eye; however, there are special considerations that must be addressed when the removal of both eyes is necessary. Patients and physicians must address psychological stressors involved in eliminating the "potential" for vision restoration bilaterally as well as other psychological considerations common to monocular procedures. Bilateral evisceration or enucleation may affect sleep/wake cycles in some patients. Important operative considerations in bilateral surgery include achieving symmetry in ocular motility, lid position, and prosthetic appearance. Finally, prosthetic factors and cosmetic results are discussed.*

CASE REPORT

A 35-year-old female with a past medical history significant for diabetes sought treatment for bilateral, blind, painful eyes. Vision loss had occurred six years earlier and was secondary to complications of diabetic retinopathy. In the six months prior to presentation, the patient had developed severe facial and ocular pain, which was worse in the left eye and was severely affecting her sleep. The patient was taking Ambien and over-the-counter cough syrup to relieve symptoms of insomnia with minimal effect. The patient noted that turning her head to the side and down helped relieve some of the pain and, therefore, she assumed this posture. The pain was also minimized when laying face down. The patient had been to multiple physicians and even had a tooth pulled to help relieve the facial pain with no benefit, (Figure 1).

The patient's ocular history is significant for a total of five surgeries and fifteen laser surgeries over a two-year period from 1997-1998 for complications of diabetic retinopathy. During this period she gradually lost vision in both eyes with complete loss of vision affecting the right, then the left eye. She left her job and started working for an equestrian program for children with various disabilities including multiple sclerosis, autism, and cerebral palsy. By the end of 1998, she had no light perception in both eyes, but she continued to work, live independently, and even ride horses. It was at this time that she started to experience symptoms of insomnia. Six years later, these symptoms were exacerbated by severe ocular pain.

On exam, the patient had no light perception in either eyes. The globes were firm bilaterally, and there was evidence of a right exotropia on motility exam. On external exam the eyelids were symmetric and in normal position. Her left eye was tender to palpation. The left eye was injected and appeared to have some exposure of a retinal band in the superior nasal quad-

William K. Blaylock

M.D.

Eastern Virginia Medical School
Norfolk, Virginia

Suzanne C. Johnston

M.D.

Ophthalmology Resident
Eastern Virginia Medical School
Norfolk, Virginia

Michael O. Hughes

Artificial Eye Clinic of Washington,
D.C.

Vienna Virginia

KEY WORDS:

evisceration, bilateral, ocular
prostheses

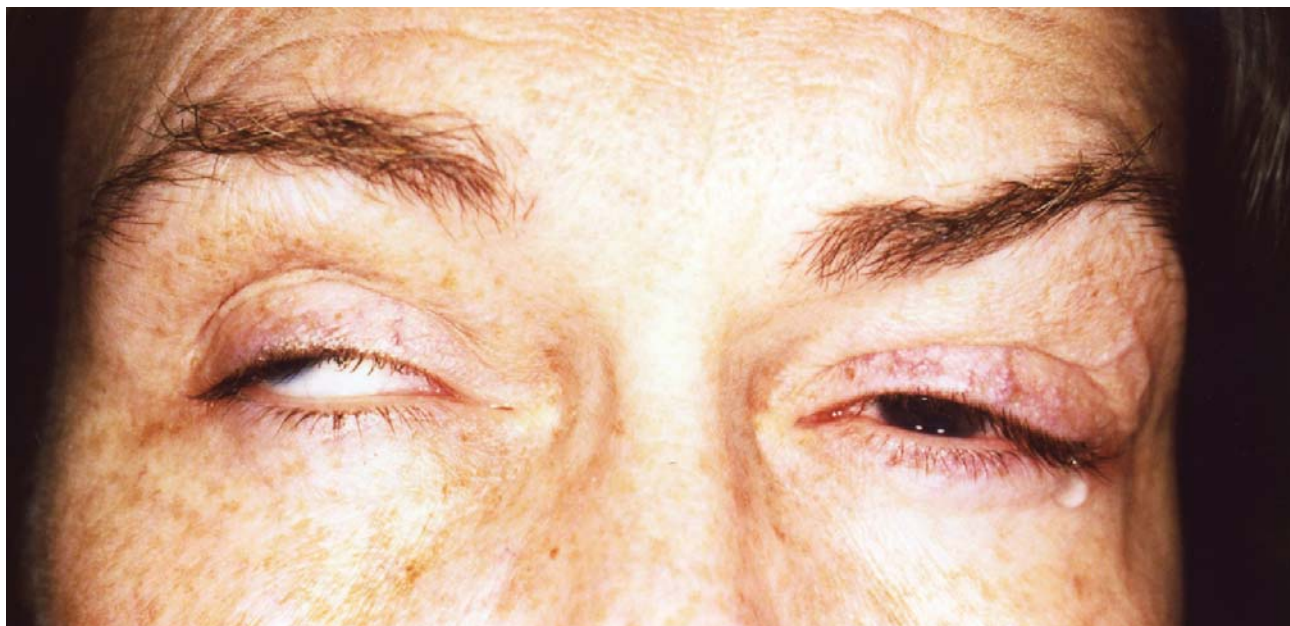

FIGURE 1 Before evisceration.

rant. The patient was aphakic bilaterally, and there was no view of the posterior pole in either eye. A CT scan showed a large buckle around each eye but was otherwise normal. There were no ocular masses. The remainder of her exam was unremarkable.

After appropriate counseling, the decision was made to eviscerate both eyes to relieve her severe bilateral ocular pain. At this time, the patient's greatest fear was losing any "potential" for vision restoration with new medical advances; however, this fear was outweighed by the desire to relieve her ocular pain.

Following the surgery, the patient experienced bilateral lid and socket edema and was treated with Bacitracin ointment as well as hot compresses. After two weeks, her pain had resolved and tarsorrhaphies were removed. One month after surgery, the edema had completely resolved. She was scheduled for a six-week post-operative evaluation and fitting by an ocularist. During this time she was also started on an antidepressant, which she continued for a year after her surgery.

On follow-up exam, the patient was wearing bilateral prostheses. Lid position was normal and symmetric with excellent color match. The patient had full ocular motility and no nystagmus. Ocular alignment was significant for a small angle intermittent esotropia, (Figure 2).

DISCUSSION

Fortunately, bilateral enucleation or evisceration is rarely indicated. An article by Bartley et al. reported six patients at the Mayo Clinic as having either simultaneous or sequential enucleation or evisceration over a 43 year period. Even so, bilateral enucleation or evisceration is sometimes necessary. Careful planning and counseling are key to attaining a positive therapeutic and cosmetic outcome.¹

Many psychological factors must be considered in the loss of an eye. These factors may be compounded by the loss of both eyes. Patients typically experience definable stages of grief after the loss of an eye including denial, awareness, anger, and acceptance. When an eye is removed secondary to pain, as in the case of the patient described, these emotions may be delayed initially because of immediate symptomatic relief. It is important to remember that patients are still likely to experience grief at a later time.² Family members may have their own feelings concerning the loss of an eye, and in some cases, this interferes with their ability to show adequate support for the patient.³ The patient described attempted to involve family members in her recovery process. For example, she encouraged her 6-year-old nephew to help her pick out her eye color. She found that by encouraging family participation, both she and her family were better able to cope with her loss.

The decision to enucleate or eviscerate eliminates any “potential” for vision restoration. This fear is obviously compounded by the prospect of having bilateral enucleation or evisceration and losing any residual hope to benefit from new medical developments. Having a bilateral procedure adds a sense of finality to bilateral visual loss.

Patients commonly experience symptoms of depression after enucleation or evisceration.⁴ Practitioners need to be prepared for these symptoms and should treat or refer patients to the appropriate specialist. This is certainly an important consideration in a patient with bilateral enucleation or evisceration.

Healing concerns in a patient with bilateral enucleation or evisceration are similar to those with monocular surgeries. Patients commonly have edema, pain, and ecchymosis after the surgery.

An acceptable cosmetic result depends on multiple factors including motility, lid position, and implant size. In a patient with a single ocular prosthesis, it is generally desirable to optimize motility in order to match the other eye. This is also desirable in patients with nystagmus and one seeing eye. Again, maximizing ocular motility helps achieve symmetry between the two eyes. In patients with bilateral prostheses, it may be desirable to limit movement of the

ocular prosthesis if patients have nystagmus or unwanted wandering eye movements.¹ However, in a patient with normal ocular motility as described in this case report, maximizing ocular motility created natural and symmetric eye movement. Lid position and implant size are also important factors to consider in bilateral procedures. If necessary, subsequent surgery may be indicated to achieve symmetry.

Recent research suggests that some blind patients have normal nocturnal spikes in melatonin secretion followed by suppression when exposed to bright light. In these patients, distinct photoreceptors function in conjunction with the retinohypothalamic tract. These photoreceptors may remain intact even after complete loss of vision. When this pathway stops functioning, the cycle of melatonin secretion is not linked to the light-dark cycle. In this case, patients have a cycle of melatonin secretion that lasts more than 24 hours. When a patient’s sleep-wake cycle does not correspond to this cycle, sleep disturbances result. Thus, in a select group of patients, bilateral enucleation or evisceration may disrupt this pathway and could potentially create sleep disturbances.^{1,5,6} Based solely on historical information, it is unlikely that the patient described in this report had significant function of the retinohypothalamic tract. The patient noticed signifi-

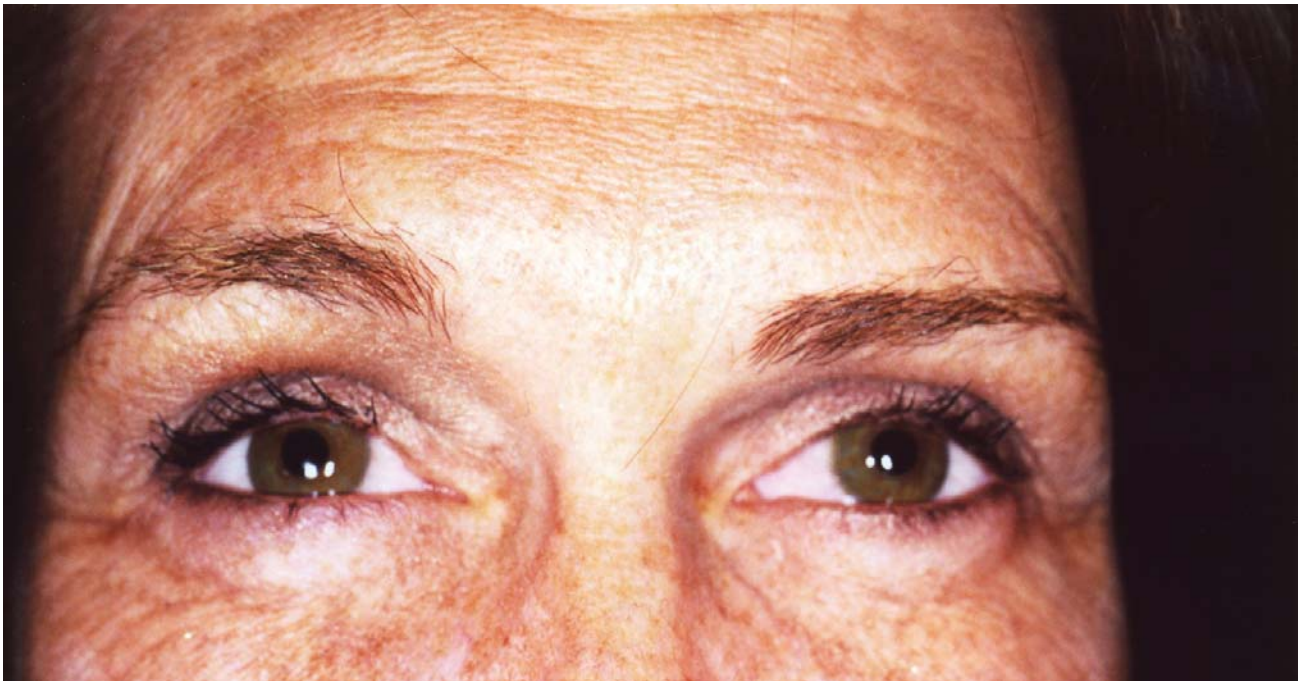


FIGURE 2 After surgery photo (complete with prostheses) shows significant relief from pain caused by her blind eyes.



FIGURE 3 Patient (third from right) with her family post-surgery.



FIGURE 4 Patient resuming “normal” life activities post-evisceration surgery.

cant alteration of her sleep-wake cycle after initial visual loss. In fact, the elimination of ocular pain by evisceration actually helped improve sleep cycles in this patient.

Other challenges for a blind patients and patients with bilateral ocular prostheses include the ability to remove and care for the prostheses. A small notch to mark the superior edge of each prosthesis allows a patient to recognize its correct orientation allowing for greater independence on the part of the wearer. It is also important that prostheses are carefully matched for color and size to create optimal ocular symmetry, (Figure 2).

Photos of the patient can be helpful in selecting iris colors, or, as in this particular instance, a family member’s iris color matched the patient’s (before surgery) irises. Larger than average pupil sizes were used because it was the opinion of the ocularist that a larger pupil (rather than a constricted size) creates a softer appearance and more natural gaze in bilateral prostheses. It cannot be overemphasized how important the patient’s family is in regard to interaction and support. In many instances where cosmetic factors seem so obvious to the practitioner (iris colors/pupil sizes), it is always best to confirm these issues with a family member or friend when fabricating prostheses for a blind patient, (Figures 3, 4).

REFERENCES

1. Bartley GB. M.D.; Siddiqui-Bradfield Y. M.D.
The Rule of Ones and Bilateral Enucleation.
Ophthalmic Plastic and Reconstructive Surgery
2000; 16(5): 313-315
2. Morris P. R.G.N, O.N.D, O.N.C. Coping with
the loss of an eye. *Nursing* 1991; 4(26): 25-7
3. Tolley FM. R.N., B.S.N.; Henninger DE. R.N.,
M.S. Perceived stressors during the recovery peri-
od following enucleation. *Insight (American*
Society of Ophthalmic Registered Nurses) 1991;
16(3): 18-19
4. Brandberg Y; Kock E; Oskar K; Trampe, EA;
Seregard S. Psychological Reactions and Quality
of Life in Patients with Posterior Uveal Melanoma
Treated Ruthenium Plaque Therapy or
Enucleation: a One Year Follow-up Study. *Eye*
2000; 14:839-46
5. Moore, RY. Vision Without Sight. *The New*
England Journal of Medicine 1995; 332(1): 54-5
6. Czeisler CA; Shanahan TL; Klerman EB; Martens
H; Brotman DJ; Emens JS; Klein T; Rizzo JF III.
Suppression of Melatonin Secretion in Some
Blind Patients by Exposure to Bright Light. *The*
New England Journal of Medicine 1995; 332(1): 6-
11

CORRESPONDENCE TO:

Suzanne Johnston, M.D.
Eastern Virginia Medical School
Department of Ophthalmology
Lions Center for Sight
600 Gresham Drive
Norfolk, VA 34507

e-mail: johnstsc@evms.edu

